



EDGE BIO CERAMIC™ SEALERS

When Flow and Biochemistry Matters



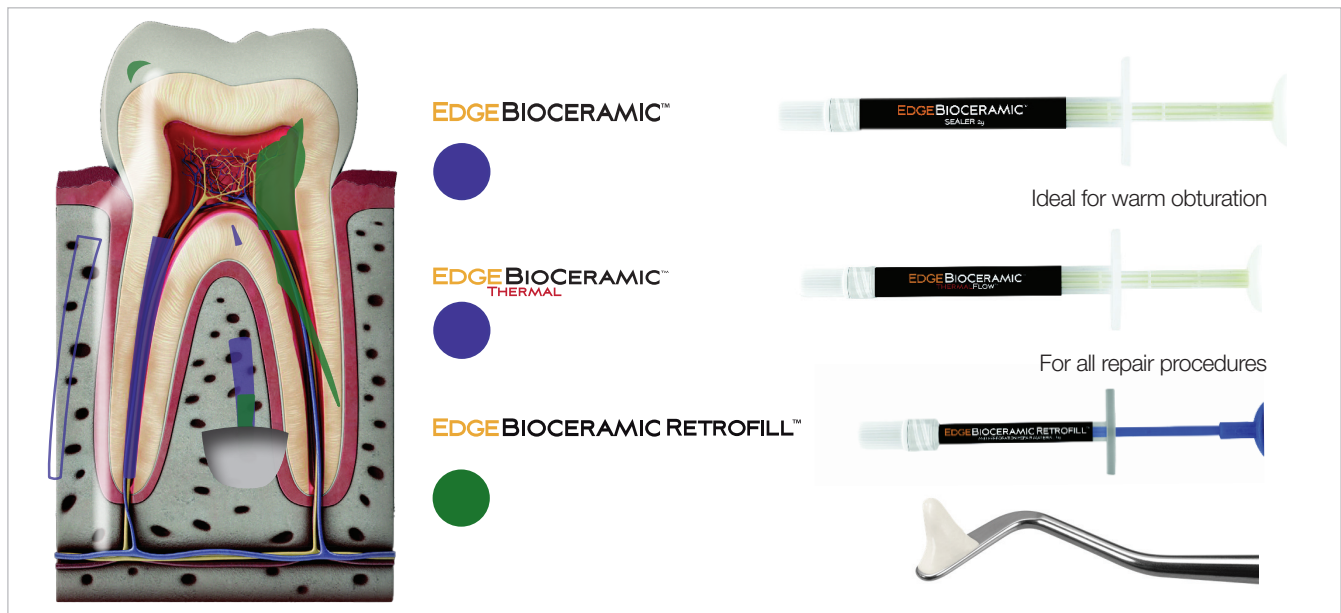
WELCOME TO EDGEBIOCERAMIC™ SEALERS

EdgeEndo's Bioceramic products are premixed bioceramics with varying viscosities, designed for specific clinical applications. These bioceramics are pure calcium silicate, calcium phosphate - based bioceramics that have been developed to repair or replace the presence of moisture naturally found in dentin.

EDGEENDO'S PURE PREMIXED BIOCERAMIC MATERIALS

- EdgeBioCeramic™ Sealer,
- EdgeBioCeramic™ ThermalFlow™ Root Canal Sealer
- EdgeBioCeramic RetroFill™ and Perforation Repair.

Patented premixed calcium silicate, calcium phosphate bioceramics designed for maximum biocompatibility, healing and optimal handling. They are also void of any non-bioceramic components such as metal and resins.



CLINICAL APPLICATIONS

- EdgeBioCeramic Sealer and EdgeBioCeramic ThermalFlow are used for obturation (ortho or retrograde as a root end filling capped with a plug of putty).

EdgeBioCeramic ThermalFlow - optimised for warm condensation methods

EdgeBioCeramic Sealer - optimised for cold hydraulic condensation.

- EdgeBioCeramic RetroFill and Perforation Repair (moldable putty) - used for all repair procedures when and where condense and strong resistance material is required to prevent washout. EdgeBioCeramic RetroFill and Perforation Repair is:

Approved for retro filling

Approved for pulp capping,

Approved for pulpotomies - Adult and Paediatric

Approved for resorptive defect repair (internal and external), apexification and apexogenesis.

EdgeEndo's comprehensive range of bioceramic products have been developed to cover endodontic material needs whilst providing superior healing and handling characteristics.

HOW DOES YOUR CURRENT SEALER COMPARE?

	EDGE BIOCERAMIC	YOUR CURRENT
Biocompatible and Osteogenic	✓	?
Superior chemical Bond of Sealer to Dentin	✓	?
Chemical Bond of Sealer to Filling Material	✓	?
Cost Effective	✓	?
Highly Antibacterial (12+ pH upon setting)	✓	?
Highly Radiopaque	✓	?
Hydrophilic	✓	?
Hydroxyapatite Producing	✓	?
Ideal Working and Setting Time	✓	?
User Friendly (Premixed Syringe Sealer)	✓	?
Zero Shrinkage of Sealer and Filling Material	✓	?
3-D Bonded Obturation at Room Temperature	✓	?

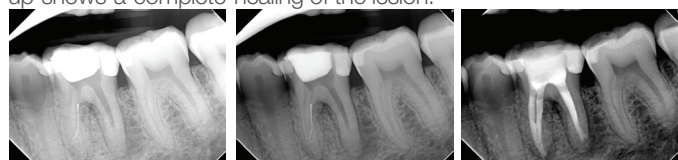
TESTIMONIALS

“EdgeBioCeramic truly shines with its exceptional composition and clinical efficacy. Clinically, its handling is ideal for daily use, consistently delivering excellent results in follow-up procedures. I am confident in its effectiveness and highly recommend it for endodontic applications.”

Dr. Biraj Patel American Trained Endodontist, Diplomate of the American Board of Endodontics (ABE)

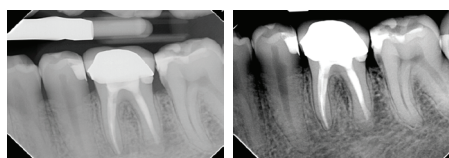
Case1: 46 years old Male patient, ASA 1, presented for the evaluation and the treatment of tooth #36. On clinical examination the tooth was sensitive to percussion and palpation. The radiographic examination showed a very large radiolucency on both mesial and distal roots, a separated instrument in the mesio-lingual canal. The diagnosis of previously initiated with symptomatic apical periodontitis was made, and the endodontic treatment was indicated.

Following anaesthesia and rubber dam placement, access was performed, and canals were located. The coronal fragment was removed and the apical fragment was bypassed. The canals were instrumented using Edge endo X7 files (EdgeEndo) to size 35.04 in the mesial canals and 40.04 in the distal canal. Canals were obturated using hydraulic condensation using EdgeBioCeramic Sealer (EdgeEndo). Bioceramic cement was used for its antibacterial and bio-active properties. The one year follow up shows a complete healing of the lesion.



Pre op

Post op

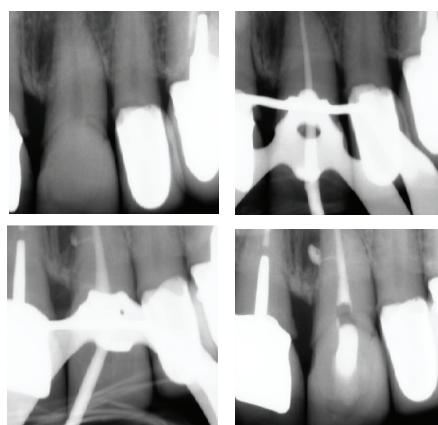


1 year follow up


“I am confident that EdgeBioCeramic stands out not just for its composition but also for its clinical efficacy. From a clinical perspective, its handling proves its suitability for every day use, thereby yielding excellent results in follow-up procedures.”

Maya Feghali, DDS, France

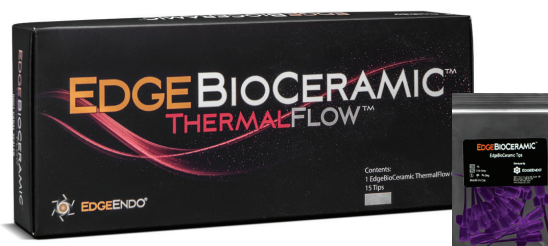Case 2: A 52-year-old female referred to the clinic for the treatment of tooth 21. Intra-oral examination showed a poor restoration on tooth 21. Percussion and palpation were negative with mobility grade 1. Radiographic examination showed an unsatisfactory restoration on tooth 21 with an apical radiolucency. After obtaining the written consent, the treatment was carried out. The area was anesthetized. Tooth was isolated using the rubber dam and access cavity was opened. The root canal used for shaping was the EdgeTaper Blaze Utopia to size F2 #25. The final irrigation protocol was performed by a continuous delivery of EDTA and NaOCl. Solutions were activated using ultrasonic activation - 1 minute per solution. Canals were dried and obturated using hydraulic condensation with EdgeBioCeramic Sealer (EdgeEndo). Lateral and secondary canals are visible on the post operative radiograph.



OBTURATION AND SURGERY HAVE BECOME EASIER WITH EDGEBIOCERAMIC™



EDGEBIOCERAMIC™ SEALER



EDGEBIOCERAMIC™ THERMALFLOW™



EDGEBIOCERAMIC™ RETROFILL



Handles like putty/Cavit*
spatula not included in packaging

Now includes
the new reduced
waste tips
which preserve
material by
62%*



PRODUCT CODE	PRODUCT DESCRIPTION	CONTENTS
EN-USEBIOCSEU	EdgeBioCeramic™ SEALER	2g syringe with 15 tips disposable tips
EN-USEBIOTFEU	EdgeBioCeramic™ THERMALFLOW™	1.5g syringe with 15 tips disposable tips
EN-USEBIORMEU	EdgeBioCeramic™ RETROFILL AND PERFORATION REPAIR MATERIAL	0.5g syringe
EN-USEBIOPTU	EdgeBioCeramic™ Replacement Tips	15 reduce waste tips

Henry Schein Australia

Building 3, Level 6
189 O'Riordan Street, Mascot, NSW 2020. Australia
www.henryschein.com.au | 1300 65 88 22

Henry Schein New Zealand

243 - 249 Bush Road, Rosedale, Auckland 0632. New Zealand
www.henryschein.co.nz | 0800 808 855

*Cavit™ is a registered trademark of 3M.

